

22. Salez Vazquez M, Biosca Florensa M. Contribucion al estudio del araneidismo. *Medna Clin* 1949; 12: 244 (as cited in ref. 25).
23. Jacobs W. Possible peripheral neuritis following a black widow spider bite. *Toxicon* 1969; 6: 299-300.
24. Russell FE, Marcus P, Streng JA. Black widow spider envenomation during pregnancy: report of a case. *Toxicon* 1979; 17: 188-189.
25. Mareic Z. Latrodectism: variations in clinical manifestations provoked by *Latrodectus* species of spiders. *Toxicon* 1983; 21: 457-466.
26. Bogen E. Poisonous spider bites: newer developments in our knowledge of arachnidism. *Ann Intern Med* 1932; 6: 375-388.
27. Newlands G, Atkinson P. Behavioural and epidemiological considerations pertaining to necrotic araneism in southern Africa. *S Afr Med J* 1990; 77: 92-95.
28. Müller GJ. Scorpionism in South Africa: a report of 42 serious scorpion envenomations. *S Afr Med J* 1993; 83: 405-411 (this issue).
29. White JAM. Snakebite in southern Africa. *CME* 1985; 3 (No. 5): 37-46.
30. Visser J. Dangerous snakes and snake bite. John Visser, P O Box 916, Durbanville, 7550.
31. Wiener S. Red back spider bite in Australia: an analysis of 167 cases. *Med J Aust* 1961; 11: 44-49.
32. Rauber AP. The case of the red widow: a review of latrodectism. *Vet Hum Toxicol* 1980; 22: suppl 2, 39-41.
33. Moss HS, Binder LS. A retrospective review of black widow spider envenomation. *Ann Emerg Med* 1987; 16: 188-191.

Scorpionism in South Africa

A report of 42 serious scorpion envenomations

G. J. MÜLLER

Abstract Forty-two cases of serious scorpion envenomation, of which 4 had a fatal outcome, are presented. The clinical profile, differential diagnosis and management of scorpionism are discussed.

Most envenomations occurred in the summer months, peaking in January and February. An immediate local burning pain was the most prominent symptom. Systemic symptoms and signs developed within 4 hours of the sting in most instances, characterised by general paraesthesia, hyperaesthesia, muscle pain and cramps. Other striking features included dysphagia, dysarthria and sialorrhoea with varying degrees of loss of pharyngeal reflexes. The blood pressure and the temperature were often raised and the tendon reflexes increased, while motor power was often impaired. In a considerable number of patients the course was complicated by varying degrees of respiratory dysfunction, which tended to be more serious in children. The outstanding feature in children was an extreme form of restlessness characterised by excessive neuromuscular activity.

Victims of scorpion sting, particularly in high-risk localities, should be closely observed for 12 - 24 hours. Children and other high-risk patients should be hospitalised. All patients with symptoms and signs of systemic envenomation should receive antivenom.

Parabuthus granulatus (Hemprich & Ehrenberg, 1828) has been identified as the most important venomous species in the western Cape. The antivenom is produced from the venom of the medically less important *P. transvaalicus* Purcell, 1899. A strong case can therefore be made for the inclusion of *P. granulatus* venom in the production of a polyvalent antivenom.

S Afr Med J 1993; 83: 405-411.

Although serious scorpion envenomations are not as common in South Africa as in certain regions of North Africa, the Middle East, India and North and South America, scorpionism is an important clinical entity in southern Africa and the sting of several local species is potentially lethal.¹⁻³ Forty-two cases of serious envenomation, 4 of which had a fatal outcome, are presented and the clinical profile and management of scorpionism is discussed.

Methods

Serious scorpion envenomations dealt with by the Tygerberg Pharmacology and Toxicology Consultation Centre from the summer of 1986/87 to the summer of 1991/92 were included in the series. In order to determine the venomous scorpion species most often responsible for serious envenomations in our region, particular attention was given to the collection of specimens implicated in incidents.

Scorpion sting causing systemic symptoms and signs is considered potentially serious, and the term scorpionism is used to describe this clinical syndrome.

Results

Of the total of 42 serious envenomations, 23 occurred in adults and 19 in children. Twenty-seven patients were treated at Tygerberg Hospital and the remainder in other localities in consultation with the author. The geographical distribution of the scorpion stings is shown in Fig. 1. All but 1 of the envenomations occurred in the spring and summer months from October to March, with a peak of 55% of cases in January and February. Seventy-five per cent of the stings took place in the evening, between sundown and midnight. Although most of the patients were stung outside the home and in the veld, 27% of the victims were stung inside the home. A sting mark was visible in only half of the 38 patients who were able to indicate the site of the sting and in these the surrounding inflammatory reaction was mild or insignificant. Of the 38 patients able to indicate the site of the sting, 28 were stung on the foot and lower leg, 7 on the hand and forearm and 3 on the back.

Department of Pharmacology, University of Stellenbosch, Parowvallei, CP

G. J. MÜLLER, B.SC., B.SC. HONS (PHARMACOLOGY),
M.B. CH.B., M.MED. (ANAESTH.)

Accepted 17 Dec 1992.

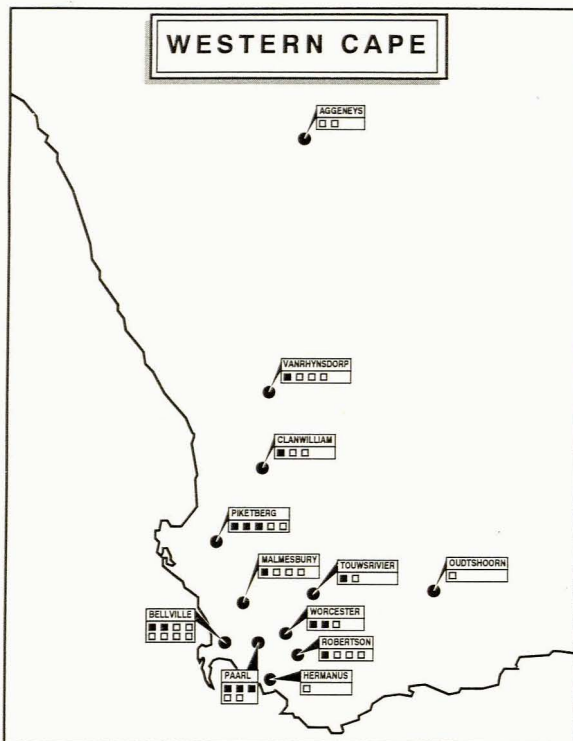


FIG. 1.
 Geographical distribution of 42 serious scorpion envenomations. Dark squares indicate incidents in which specimens were obtained for identification.

Prominent symptoms and signs of serious scorpion envenomations documented in this case series are summarised in Fig. 2. In the figure, the data on the children (< 13 years) is separated from that of the older age group because of marked differences in the clinical profiles. Although systemic symptoms and signs developed within 4 hours of the sting in most patients, onset in 4 adult patients was delayed from 4 to 12 hours.

Sixteen patients, 10 children and 6 adults, presented with difficulty in breathing or respiratory distress (Table I). Four of these, all of them children, died. Of the remaining 12 patients, 8 (5 children) required mechanical ventilation, and the mean assisted ventilation time was 2,4 days (range 10 hours - 6 days). One child was intubated to protect his airway but was not ventilated, and 3 adults were treated with mask oxygen only. The arterial blood gas values for 11 of the 12 patients are shown in Table II.

One patient presented with transitory ventricular extrasystoles and another with bradycardia. No abnormalities in cardiac rhythm could be demonstrated on ECG. Blood pressures in the 16 patients who presented with a hypertensive response ranged from 140/90 mmHg to 200/130 mmHg.

An interesting sign, elicited in 6 of the 11 adults with hyperactive tendon reflexes, was a marked prolongation of the relaxation phase of the ankle reflex.

Antivenom was given intramuscularly to 35 patients in an average dose of 10 ml; 22 patients received antivenom within 6 hours of the sting, 11 within 24 hours, 1 after 48 hours and 1 on day 5. None of the patients responded dramatically, as is seen when antivenom is used in the treatment of latrodectism.⁴ It was consequently difficult to distinguish between a sponta-

PROMINENT SYMPTOMS AND SIGNS OF SCORPIONISM DOCUMENTED IN THIS CASE SERIES

SYMPTOMS	Adults and adolescents (n = 23)	Children (< 13 years) (n = 19)
Severe pain at sting site	96%	79%
Paraesthesia	74%	11%
Difficulty in swallowing, "thick tongue"	70%	26%
General feeling of weakness	61%	26%
Generalized muscle pain and cramps	57%	11%
Trembling	52%	5%
Hyperaesthesia	43%	5%
Increased salivation	30%	63%
Anxiety	26%	68%
Visual disturbances	26%	5%
Difficulty in breathing	22%	42%
Increased sweating	22%	0%
Nausea, vomiting, diarrhoea	9%	0%
Headache	9%	5%
SIGNS		
Dysphagia, dysarthria	70%	47%
Tremors, involuntary movements	57%	32%
Sting mark evident	57%	32%
Raised blood pressure	48%	32%
Hyperactive stretch reflexes	48%	5%
Decreased motor power	43%	26%
Raised temperature	43%	32%
Incoordination, ataxia	39%	42%
Hyperactivity, restlessness	39%	84%
Increased salivation	35%	68%
Increased sweating	26%	5%
Ptosis	26%	16%
Respiratory depression	26%	53%
Retention of urine	22%	11%
Tachycardia	22%	42%
Absent gag reflex	9%	21%

FIG. 2.
 Prominent symptoms and signs of scorpionism documented in this case series.

neous resolution and the effect of antivenom. The efficacy of the antivenom was especially questionable in 10 of the 12 survivors who presented with respiratory dysfunction (Table I). No instances of an allergic response to the antivenom or other adverse reactions were reported. Three patients did not receive antivenom owing to a mild form of systemic involvement. The 4 children who died were among the 7 patients who did not receive antivenom. One child died *en route* to hospital 1½ hours after being stung, another died suddenly in a small regional hospital 4 hours after envenomation, the 3rd died in hospital during a resuscitation attempt 3 - 4 hours after the incident, and the 4th aspirated stomach contents 1 - 2 hours after being stung, which led to the development of respiratory distress syndrome. She died in an intensive care unit, 2½ days later, from complications of aspiration.

The results of various laboratory and radiographic investigations, performed on 22 patients who recovered completely, were as follows: 7 patients had a moderately elevated white cell count ranging from 11 to $24 \times 10^9/l$ (the serum electrolyte values of these patients were normal), the blood glucose value was raised in 8 of 13 patients, 4 out of 6 had raised creatine kinase levels, and ECGs performed on 10 were normal. Four of 8 patients who were mechanically ventilated in Tygerberg Hospital showed signs of aspiration pneumonia on the chest radiograph.

Of the 15 scorpion specimens obtained which were responsible for stings, 14 were identified as *Parabuthus granulatus* and 1 as *P. capensis* (Hemprich & Ehrenberg, 1828) (Fig. 1). The 14 *P. granulatus* specimens have been deposited in the national collection of Arachnida (Plant Protection Research Institute, Pretoria) for reference purposes. The specimen identified as *P. capensis* has been lost and is thus not available for verification.

Discussion

Statistics on the incidence of scorpion sting in South Africa are not available. Although most scorpion stings induce local pain and a slight local inflammatory reaction only, serious envenomations do occur and can be life-threatening. The Tygerberg Pharmacology and Toxicology Consultation Centre is approached for advice on the management of scorpion stings on average 30 - 40 times in a season; since most consultations emanate from medical practitioners, a relatively high proportion of cases (25%) are of a serious nature.

Two scorpion families occur in southern Africa, namely the Buthidae and Scorpionidae.⁵ The potentially dangerous and medically more important species all belong to the Buthidae family. The Buthidae are easily distinguishable from the Scorpionidae by their thick tails and slender pincers (pedipalps) while the relatively harmless Scorpionidae have large, powerful pincers and thin tails (Fig. 3). The Buthidae family is represented by 5 genera of which *Parabuthus*, *Buthotus* and *Uroplectes* are more important. *Parabuthus* is the largest (50 - 140 mm long) and medically the most important genus. This genus comprises approximately 20 species, and they are distinguished from other scorpions by the presence of stidulatory granules on the dorsal surface of the first two 'tail' segments. They are nocturnal and dig shallow burrows or scrapes at the base of shrubs, under rocks or fallen trees, and in soils of variable hardness and texture ranging from consolidated sand to moderately hard and gritty sediments. Some, for example *P. granulatus*, are often found in human habitations. Fig. 4 depicts the distribution of *Parabuthus* in southern Africa. The medium-sized *Buthotus* species (30 - 60 mm long) are restricted to Namaqualand and the northern Transvaal. *Uroplectes*, the smallest and the least toxic of

the three genera, is widely distributed throughout South Africa.^{5,6}

Scorpion venom is injected by means of a stinger located at the tip of the telson, the terminal segment of the 'tail'. The bulbous portion of the telson, also known as the vesicle, contains two venom glands, each with a duct opening on each side near the tip of the stinger.⁷ During the stinging process, muscles attached to the exoskeleton on each side of the gland contract, injecting the venom through the orifices. In addition, certain species of *Parabuthus* with large venom vesicles are able to squirt or spray their venom when alarmed suddenly.⁸

Although variations in the symptoms and signs of scorpion envenomation do occur, the clinical profile of scorpionism is essentially similar in different regions of the world.⁹ The syndrome primarily reflects a state of generalised neurological hyperexcitability and other excitable tissue, such as skeletal and heart muscle, may also be affected.^{2,3,10,11} Scorpion venoms are complex, aqueous mixtures containing mucus, inorganic salts, low-molecular-weight organic molecules and many different small basic proteins ($M_r < 8\ 000$), which are the neurotoxins. The neurotoxins act on sodium channels of excitable cells, either by retarding inactivation (an α -toxin) or enhancing activation (a β -toxin) leading to spontaneous depolarisation of excitable cells. The overall effect is a tendency of the neuron to fire spontaneously and repetitively.^{2,3,12} Noradrenaline and acetylcholine are released from adrenergic and cholinergic nerve endings, respectively, and adrenaline is released from the adrenal medulla.^{3,13-15} These mechanisms may explain the sympathetic, para-sympathetic and skeletal muscle effects of scorpion venom.¹¹ Symptoms and signs of increased sympathetic activity include hypertension, tachycardia, cardiac dysrhythmias, increased perspiration, fever, hyperglycaemia and restlessness.^{2,11} An increase in catecholamine levels has been demonstrated in severe envenomations.³ Hypertension may also be induced by an increase in renin release.¹⁶ Reported parasympathetic effects include increased salivation, bradycardia, hypotension and gastric distension.¹¹ Tremors and involuntary movements seen in scorpionism are due to excessive somatic neuromuscular activity.² Although the muscular weakness, difficulty in breathing and bulbar paralysis could be explained by a phase of neurotransmitter depletion, some other unexplained central mechanisms may well be involved.

The spectrum and degree of symptoms and signs of systemic envenomation is determined by several factors, including the scorpion species involved, the body mass of the victim (children are more vulnerable than adults), the amount of venom injected, and the physical health of the patient.³ The clinical presentation of scorpionism in the under-13-year-old age group differs in many respects from that in the older patient (> 13 years). This could be due in part to a communication problem as well as difficulties in eliciting certain signs in a child presenting with extreme restlessness.

The clinical profile of southern African scorpionism can be described as follows:

The typical victim, barefoot or wearing sandals at the time of the incident, is stung on the foot, after sundown, outside the home. Immediate pain is the most prominent symptom, often described as burning and of an excruciating intensity. The pain lasts for a variable period, usually extending from hours to 1 day and sometimes even longer. It is usually accompanied by local paraesthesia and pronounced hyperaesthesia. In the normal course most adult patients become aware of paraesthesia in the hands and feet within 1 - 4 hours of being stung. Paraesthesia may also be experienced in the scalp, around the mouth or in other areas of the face. Generalised hyperaesthesia, muscle pain and cramps are




FIG. 3. Left: the potentially lethal *P. granulatus*, displaying slender pincers (pedipalps) and a relatively thick 'tail'; right: a species of the relatively harmless Scorpionidae, with large, powerful pedipalps and thin 'tail'.

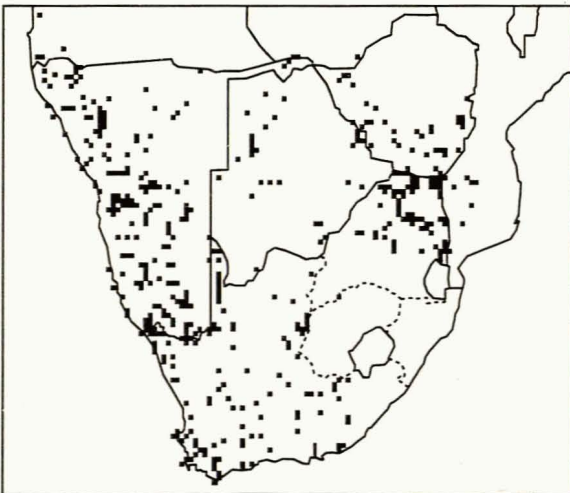


FIG. 4. Geographical distribution of the scorpion genus *Parabuthus* in southern Africa.

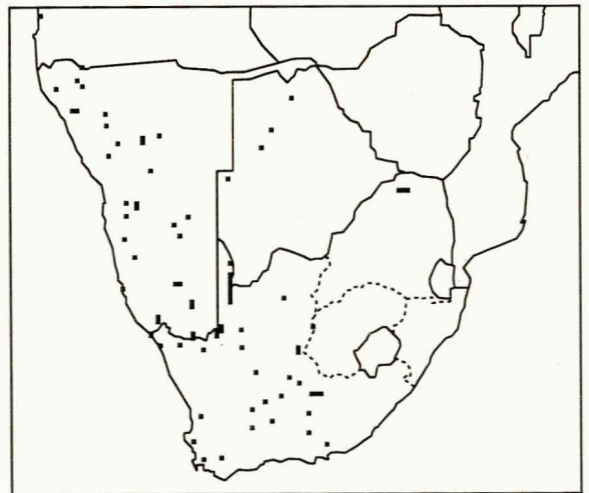


FIG. 5. Geographical distribution of *Parabuthus granulatus* in southern Africa.

prominent. Every movement and surface contact, such as friction from sheets and bed clothes, causes pain. Some patients describe a sensation of vibration and experience a feeling akin to an electrical current moving through the body, and many complain of difficulty in swallowing and increased salivation. General weakness, reflected in difficulty in walking, is a common symptom. Some patients experience visual disturbances and a substantial number have difficulty breathing.

On examination, the adult patient is anxious and obviously in pain. Tremors and involuntary movements are pronounced. Striking features are dysphagia, dysarthria and drooling with varying degrees of loss of the pharyngeal reflexes. Increased salivation is probably due to bulbar paralysis rather than to parasympathetic stimulation. The mechanism responsible for the bulbar paralysis is difficult to explain. Whether or not the venom has a predilection for the IXth, Xth and XIIth

cranial nerves and their central connections, needs to be explored. The blood pressure and temperature are often raised and the tendon reflexes are hyper-reactive. The relaxation phase of the ankle reflex is occasionally delayed, and clonus may be present. The cause of these is not clear.

There is a general decrease in motor power and if the adult patient is able to walk at all he or she does so ataxically in a gait similar to that seen in alcohol intoxication. Some patients walk in a stiff-legged manner as if to avoid bending their knees. Ptosis, an increase in perspiration and retention of urine occur in a substantial number of patients.

Although children may present with symptoms and signs similar to those seen in adults, the most outstanding clinical feature is a unique form of restlessness.^{2,10} The restlessness should not simply be interpreted as a reaction to pain but should rather be recognised as a severe form of systemic envenomation. It is characterised by crying and screaming, uncontrollable jerking of the extremities, chaotic thrashing movements, flailing and writhing. The patient is unable to lie still and is difficult to restrain. He or she may assume an unnatural posture and contract the face in a simulated chewing motion, with grimaces and smacking of the lips. The behaviour is completely out of character and abnormal to the extent that those present gather to observe the spectacle. Excessive neuromuscular activity may sometimes be mistaken for convulsions or mimic the central effects of an overdose of neuroleptics, tricyclic antidepressants or anticholinergics.¹ The restlessness caused by scorpionism in children has been described as 'extraordinary and duplicated by little else in medicine'.¹⁰ The smaller child or infant may, however, present with unexplained crying only. The mechanism responsible for the central effects of scorpion venom is difficult to explain. Some authors have suggested that the increase in the concentrations of circulating catecholamines may

be responsible, but this is not convincing since these rather polar substances do not readily cross the blood-brain barrier.^{17,18}

Bulbar paralysis, accompanied by respiratory distress, is more frequent in children than in adults and tends to be more severe.

Respiratory failure is the most dangerous feature of severe scorpionism and was probably the primary cause of death in the 4 victims referred to above. In an analysis of blood gases performed in 11 of the 12 survivors with respiratory dysfunction, 3 showed alveolar hypoventilation. They either had muscular weakness or central depression. This impression is supported by a raised partial arterial carbon dioxide pressure (Paco₂) (range 5.7 - 8.1 kPa). All patients had either low ventilation/perfusion ratios or pulmonary shunts. This is supported by the fact that the alveolar-arterial oxygen tension difference was raised (mean (± SD) 11.87 ± 1.42 kPa; N = 11) (Table II). This could be due to aspiration of pharyngeal and oral secretions caused by bulbar paralysis, a decrease in lung volume secondary to a change in chest muscle tone with or without aspiration, or cardiogenic or non-cardiogenic lung oedema. Any of these factors could have contributed to respiratory distress. However, severe cardiovascular manifestations such as cardiac dysrhythmias, pulmonary oedema and cardiac failure, which are often associated with scorpionism in other regions of the world, did not feature prominently in this series.^{15,19-20} Although a high percentage of patients presented with raised blood pressure, it was not a consistent finding in those with marked respiratory dysfunction. Symptoms and signs of bulbar paralysis did, however, feature in 14 of the 16 patients with respiratory dysfunction (Table I). It would therefore be reasonable to assume that a central neurological mechanism played an important role in the pathogenesis of respiratory failure of these victims.

This series has identified *P. granulatus* as being the

TABLE I.
Details of patients with respiratory dysfunction

Age (yrs)	Bulbar paralysis	Blood pressure (mmHg)	Resp. support or mech. ventilation	Scorpion identified	Antivenom administered	Death
10*	+	140/100	Ventilated (10 h)	-	+(within 6 h)	-
4	?	?	-	+	-	+
6	?	?	-	-	-	+
19*	+	200/130	Ventilated (48 h)	+	+(within 6 h)†	-
2*	+	72/40	Ventilated (72 h)	-	+(within 6 h)†	-
54*	+	170/110	Mask O ₂ (48 h)	+	+(within 6 h)†	-
34*	+	150/90	Ventilated (96 h)	-	+(at 18 h)†	-
3	+	?	Resuscitation attempted	-	-	+
45*	+	160/90	Ventilated (48 h)	+	+(at 24 h)†	-
4*	+	140/96	Ventilated (144 h)	-	+(at 120 h)	-
30*	+	110/70	Mask O ₂ (12 h)	-	+(within 6 h)†	-
12*	+	150/70	Ventilated (24 h)	+	+(within 6 h)†	-
2½*	+	?	Ventilated (24 h)	+	+(within 6 h)†	-
4	+	110/70	Intubated for 12 h, not ventilated	+	+(within 6 h)	-
6	+	90/60	Ventilated (48 h)	-	-	+
26*	+	180/100	Mask O ₂ (36 h)	+	+(at 8 h)†	-

* Arterial blood gas values of these patients were used to calculate values in Table II.

† Efficacy of antivenom questionable.

? = not known.

TABLE II.
Arterial blood gas values (mean ± SD) in 11 patients with respiratory dysfunction

Pao ₂ (kPa)	Fio ₂ (kPa)	Paco ₂	A-aDo ₂	pH	HCO ₃ ⁻ (mEq/l)
13.68	0.33	5.06	11.87	7.36	21.98
± 1.58	± 0.02	± 0.41	± 1.42	± 0.04	± 0.85

Pao₂ = arterial oxygen tension; Fio₂ = fractional inspired oxygen concentration; Paco₂ = arterial carbon dioxide tension; A-aDo₂ = alveolar-arterial oxygen tension gradient; HCO₃⁻ = plasma bicarbonate concentration.

most important venomous scorpion species in our region. Fig. 5 depicts the geographical distribution of *P. granulatus* in southern Africa. The importance of *P. granulatus* is further confirmed by 2 case reports unrelated to the present study. A 5-year-old child died 1 hour after being stung by a scorpion which was positively identified by a professional arachnologist as *P. granulatus*, and a preserved specimen involved in another serious incident of envenomation more than a decade ago has recently also been identified as *P. granulatus*.^{27,28} As already indicated, a single incident with a lethal outcome ascribed to *P. capensis* could not be satisfactorily verified.

The antivenom currently available is produced by the South African Institute for Medical Research from the venom of the medically less important *P. transvaalicus*.²⁹ In view of the questionable efficacy of the existing antivenom experienced in many of our cases, a strong case could be advanced for the inclusion of the venom of *P. granulatus* in the production of a polyvalent antivenom.

The diagnosis of scorpionism can sometimes be difficult in the absence of a firm history of a sting and particularly in children. Conditions which should be considered in a differential diagnosis include the following:

Spider bite. Although different mechanisms of action are involved, both scorpion and widow spider venoms (genus: *Latrodectus*) cause an increase in the release of peripheral neurotransmitters, resulting in some similarities between latrodectism and scorpionism.⁴ Classic symptoms and signs of scorpionism usually not found in latrodectism include dysphagia with marked sialorrhoea, difficulty in breathing, visual disturbances and pronounced general hyperaesthesia. Profuse sweating and abdominal muscle rigidity, on the other hand, are much more prominent in latrodectism. Cytotoxic spider bites are not associated with neurotoxic effects and are therefore not considered in the differential diagnosis.

Snake bite. In a substantial number of neurotoxic snake bites, as in scorpion sting, the bite site is either insignificant or cannot be located.³⁰ Both Mamba and Cape Cobra bites can cause visual disturbances, ptosis and dysphagia as well as difficulty in breathing in the early stages of envenomation. Most of the patients will, however, rapidly progress to a state of complete flaccid paralysis within 1 - 4 hours. Although berg adder venom, which is partly neurotoxic, can induce marked ptosis and occasionally dysphagia, other prominent symptoms and signs include complete ophthalmoplegia, and disturbances of smell and taste. A local inflammatory reaction with marked tissue oedema is also typical of berg adder bite.³¹

Organophosphate poisoning. Both organophosphate poisoning and scorpion envenomation can cause a state of anxiety and restlessness, muscular twitching, increased salivation, decrease in motor power, raised blood pressure, tachycardia and respiratory distress. It is possible that an increase in the concentration of acetylcholine in the synaptic cleft, induced by both scorpion venom and organophosphate poisoning, is responsible for many of the similarities.

Drug overdose. Neuroleptic drug overdose in children typically presents with confusion, restlessness, slurred speech, dysarthria, difficulty in swallowing, painless spasms, hypertonicity and tremors; however, sialorrhoea, a prominent feature of scorpion sting, is not associated with an overdose of these agents. Other types of drug overdose to be considered in children with restlessness, hyperactivity and abnormal behaviour are the anticholinergics and tricyclic antidepressants.³²

Guillain-Barré syndrome. This syndrome is characterised by a rapid onset of peripheral and cranial nerve

dysfunction.³³ Both scorpionism and the Guillain-Barré syndrome can present with paraesthesia, decreased motor power, dysphagia, dysarthria, autonomic nervous system dysfunction and respiratory distress. Scorpionism is usually more rapid in onset and resolves within 5 - 7 days.

Tetanus. Although tetanus is characterised by pronounced rigidity and reflex muscle spasm, excessive muscular activity of early or milder forms of tetanus could conceivably be confused with those seen in severe scorpionism.³⁴ Both tetanus and scorpionism can present with dysphagia and excessive oropharyngeal secretions, respiratory distress and autonomic nervous system instability characterised by tachycardia, sweating and wide variations in blood pressure.

Other conditions that should be considered in the differential diagnosis include poliomyelitis, botulism, myasthenia gravis, encephalitis, meningitis, subdural haematoma and diphtheria.

Treatment

The approach to the management of scorpion sting will be influenced by the body mass and physical health of the victim and the scorpion species involved. Identification of a scorpion down to species level is difficult, however, and can only be accomplished by an expert; the traditional rule of thumb that scorpions with thick tails and slender pedipalps (pincers) are more venomous than those with slender tails and large pedipalps is therefore a more useful guide for the clinician (Fig. 3). Unfortunately the scorpion involved is recovered in only 20 - 30% of cases at best. Another useful guideline is that the more venomous scorpions occur west of a longitudinal line passing through Bloemfontein, and in areas of the northern and north-eastern Transvaal; the chances of a serious scorpion envenomation occurring in Pietermaritzburg or Umtata as opposed to Cape Town or Piketberg are remote.

A victim of scorpion sting, especially in a high-risk area, should be closely observed for 12 - 24 hours and it is recommended that children and other high-risk patients be hospitalised. All patients with symptoms and signs of systemic envenomation should be given 10 ml of scorpion antivenom intramuscularly. The reduction or loss of upper respiratory protective reflexes and the development of respiratory distress is the most serious complication of scorpionism. Early intervention is necessary to secure and protect the airway and to provide appropriate ventilatory support.²⁸ As scorpion venom induces autonomic nervous system instability, patients with serious envenomations should be closely monitored for the development of cardiac dysrhythmias, severe hypertension, hypotension and pulmonary oedema.²⁴ The use of atropine to reduce secretions is not advisable as this may lead to unopposed adrenergic responses. Intravenous fluid therapy should also be closely supervised to prevent vascular overload.

Children presenting with restlessness should not be given any central nervous system depressants, e.g. opiates or benzodiazepines. These will not only aggravate the respiratory depression but increase the risk of emesis and aspiration. However, sedation may be indicated to allow intubation and ventilation.

The only effective treatment for the local pain is infiltration of the sting site with a local anaesthetic agent. Opiates are relatively ineffective and increase the risk of respiratory depression. Experience with non-steroidal anti-inflammatory agents is also disappointing. Although some authors recommend that crushed ice be applied to the sting site, most patients will not allow this due to the local hyperaesthesia. Intravenous administration of calcium gluconate is moderately effective for the

relief of generalised muscle pain and cramp, but its effect lasts for 20 - 30 minutes only and there is a limit to the amount that can be administered safely

The routine use of antihistamines and glucocorticosteroids is not recommended unless they are administered to decrease the severity of a possible allergic reaction to the antivenom.

Scorpion antivenom is a refined equine serum globulin and the dose recommended in the package insert is 10 ml intramuscularly.²⁹ Snake antivenom, on the other hand, which is prepared by a process identical to that used in the production of scorpion antivenom, is given intravenously. It seems, therefore, that there is no real contraindication to the administration of scorpion antivenom intravenously. In view of the disappointing therapeutic response to intramuscular scorpion antivenom and the absence of any valid objection to the administration of scorpion antivenom intravenously, we propose to evaluate the efficacy and safety of sufficiently diluted antivenom by this route in seriously envenomated patients.

This paper forms part of a Ph.D. project registered at the University of Stellenbosch by G. J. Müller.

The contribution by Professor A. R. Coetzee, head of the Department of Anaesthesiology, in the interpretation of blood gas values is gratefully acknowledged. The author is indebted to Dr G. Newlands for his permission to use the distribution maps in Figs 4 and 5, and thanks Dr J. G. L. Strauss, Chief Medical Superintendent of Tygerberg Hospital, for permission to publish.

REFERENCES

- Curry SC, Vance MV, Ryan PJ, Kunkel DB, Northey WT. Envenomation by the scorpion *Centruroides sculpturatus*. *J Toxicol Clin Toxicol* 1983; 84; 21: 417-449.
- Warrell DA. Animal poisons. In: Manson-Bahr PEC, Bell DR, eds. *Manson's Tropical Disease*. London: Baillière Tindall, 1987: 855-898.
- Watt DD, Simard JM. Neurotoxic proteins in scorpion venom. *J Tox Tox R* 1984; 3: 181-221.
- Müller GJ. Black and brown widow spider bites in South Africa: a series of 45 cases. *S Afr Med J* 1993; 83: 399-405 (this issue).
- Newlands G. Review of southern African scorpions and scorpionism. *S Afr Med J* 1978; 54: 613-615.
- Lamoral BH. The scorpions of Namibia (Arachnida: Scorpionida). *Ann Natal Mus* 1979; 23: 497-784.
- Newlands G, Martindale CB. The buthid scorpion fauna of Zimbabwe-Rhodesia with checklists and keys to the genera and species, distributions and medical importance. *Z Angew Zool* 1980; 67: 51-77.
- Newlands G. Ecological adaptations of Kruger National Park Scorpionids (Arachnida: Scorpionides). *Koedoe* 1972; 15: 37-48.
- Amitai Y, Mines Y, Aker M, Goitein K. Scorpion sting in children: a review of 51 cases. *Clin Pediatr* 1985; 24: 136-140.
- Rimsza ME, Zimmerman DR, Bergeson PS. Scorpion envenomation. *Pediatrics* 1980; 66: 298-302.
- Rachesky IJ, Banner W, Dansky J, Tong T. Treatments for *Centruroides exilicauda* envenomation. *Am J Dis Child* 1984; 138: 1136-1139.
- Watt DD, Simard JM, Meves H. Chemistry and biological activities of neurotoxins from scorpion venoms. *J Tox Tox R* 1990; 9: 50-51.
- Diniz CR, Torres JM. Release of an acetylcholine-like substance from guinea pig ileum by scorpion venom. *Toxicon* 1968; 5: 277-281.
- Romey G, Abita JP, Chicheportiche R, Rochat H, Lazdunski M. Scorpion neurotoxin: mode of action on neuromuscular junctions and synaptosomes. *Biochim Biophys Acta* 1976; 448: 607-619.
- Ismail M, Ghazal A, El-Fakahany EE. Cardiovascular effects of venom from the scorpion *Buthus occitanus*, Amoreux. *Toxicon* 1980; 18: 327-337.
- La Grange RG. Elevation of blood pressure and plasma renin levels by venom from scorpions, *Centruroides sculpturatus* and *Leiurus quinquestriatus*. *Toxicon* 1977; 15: 429-433.
- Sofer S, Gueron M. Respiratory failure in children following envenomation by the scorpion *Leiurus quinquestriatus*: hemodynamic and neurological aspects. *Toxicon* 1988; 26: 931-939.
- Hoffman BB, Lefkowitz RJ. Catecholamines and other sympathomimetic drugs. In: Gilman AG, Rall TW, Nies AS, Taylor P, eds. *Goodman and Gilman's The Pharmacological Basis of Therapeutics*. New York: Pergamon Press, 1990: 187-220.
- Gueron M, Stern J, Cohen W. Severe myocardial damage and heart failure in scorpion sting: report of five cases. *Am J Cardiol* 1967; 19: 719-726.
- Gueron M, Yaron R. Cardiovascular manifestations of severe scorpion sting: clinicopathologic correlations. *Chest* 1970; 57: 156-162.
- Gueron M, Adolph RJ, Grupp IL, Gabel M, Grupp G, Fowler NO. Hemodynamic and myocardial consequences of scorpion venom. *Am J Cardiol* 1980; 45: 979-986.
- Bawaskar HS. Diagnostic cardiac premonitory signs and symptoms of red scorpion sting. *Lancet* 1982; 1: 552-554.
- El-Amin EO, Elidrisy A, Hamid HS, Sultan OM, Safar RA. Scorpion sting: a management problem. *Ann Trop Paediatr* 1991; 11: 143-148.
- Gueron M, Ovsyshcher I. What is the treatment for cardiovascular manifestations of scorpion envenomation? *Toxicon* 1987; 25: 121-124.
- Freire-Maia L, Campos JA. On the treatment of the cardiovascular manifestations of scorpion envenomation. *Toxicon* 1987; 25: 125-130.
- El-Amin EO. Issues in management of scorpion sting in children. *Toxicon* 1992; 30: 111-115.
- Petersen J. Death due to a scorpion sting. *S Afr Med J* 1987; 71: 406.
- Smith LR, Potgieter PD, Chappell WA. Scorpion sting producing severe muscular paralysis. *S Afr Med J* 1983; 64: 69-70.
- Scorpion venom antiserum. Package insert. South African Institute for Medical Research, Rietfontein, Edenvale, Transvaal (PO Box 28999, Sandringham, 2131).
- White JAM. Snakebite in southern Africa. *CME* 1985; 3 (No. 5): 37-46.
- Ellis CG. The berg adder: a unique snake. *Practitioner* 1979; 223: 544-547.
- Ellenhorn MJ, Barceloux DG. *Medical Toxicology: Diagnosis and Treatment of Human Poisoning*. New York: Elsevier, 1988.
- Pleasure DE, Schotland DL. Acquired neuropathies. In: Rowland LP, ed. *Merritt's Textbook of Neurology*. Philadelphia: Lea & Febiger, 1989: 609-625.
- Adams EB. Tetanus. In: Weatherall DJ, Ledingham JGG, Warrell DA, eds. *Oxford Textbook of Medicine*. Oxford: Oxford University Press, 1988: 5.265-5.270.