

Scorpion Stings in Animals: Diagnosis and Treatment



Dr Roulene Sheridan, Moorreesburg Animal Hospital, Moorreesburg, 022

433 4883, moorreesburg@tah.co.za

Dr Derette Kotze, Long Acres Animal Hospital, Langebaan, 022 772 0019,

longacresvet@yahoo.com

Very little is known or published about scorpion stings in our domestic animals. This document will propose a treatment protocol, based on articles on scorpion stings in humans as well as personal communications with veterinarians who have treated animals stung by scorpions.

Introduction

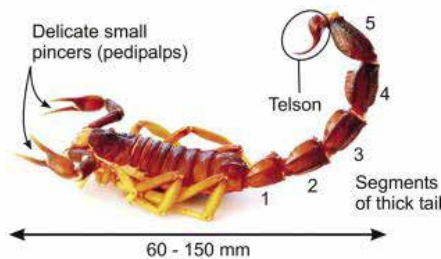
Four scorpion families have been identified in southern Africa: *Scorpionidae*, *Buthidae*, *Bothriuridae* and *Liochelidae*. Of these, *Scorpionidae* (42%) and *Buthidae* (34%) are the most abundant and responsible for the most scorpion stings. The potentially dangerous and medically important species all belong to the *Buthidae* family. The *Buthidae* are easily distinguishable from the *Scorpionidae* by their thick tails and slender pincers (pedipalps), whereas the relatively harmless *Scorpionidae* have large, powerful pincers and thin tails.¹ This is where the traditional rule of thumb comes from: scorpions with thick tails and slender pincers are more venomous than those with slender tails and large pincers (Fig. 1).

Seven genera have been identified in the *Buthidae* family. The genus *Parabuthus* is medically the most important. Of the 22 *Parabuthus* species that occur in southern Africa, only two, namely *P. granulatus* and *P. transvaalicus* have been shown to be associated with serious envenomings. From LD50 studies in mice it has been shown that *P. granulatus* is three times more venomous than *P. transvaalicus*. Clinical studies have also found that *P. granulatus* envenoming is associated with a



Fig. 1 Left: the potentially lethal *Parabuthus granulatus* scorpion. Right: a scorpion species of the relatively harmless *Scorpionidae* family.¹

Parabuthus granulatus



Parabuthus transvaalicus




Fig. 2 General morphology of *P. granulatus* and *P. transvaalicus*.¹

higher morbidity and mortality compared with *P. transvaalicus*.¹

P. granulatus and *P. transvaalicus* are very large scorpions, measuring 60 - 150 mm in length. *P. granulatus* is light to dark brown in colour whereas *P. transvaalicus* is dark brown to uniformly black (Fig 2).^{1,6}

Different species occur in different areas of South Africa. Another useful guideline is that the more venomous scorpions occur west of a longitudinal line passing through Bloemfontein, and in areas of Limpopo and Mpumalanga; the chances of a serious scorpion envenomation occurring in Pietermaritzburg or Umtata as opposed to Cape Town or Piketberg are remote.⁸ Fig. 3 gives an indication of which species might be more prevalent in certain areas.

Scorpions are mostly active during the summer months and most species are nocturnal.^{1,6}

October to March is the period when most stings occur (peak in January/February) with about 75% of stings in humans occurring at night.^{2,6}

Parabuthus species dig shallow burrows or scrapes at the base of shrubs, under rocks or

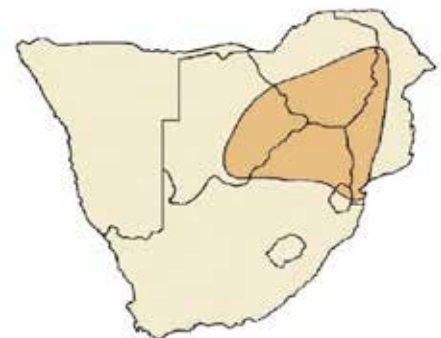
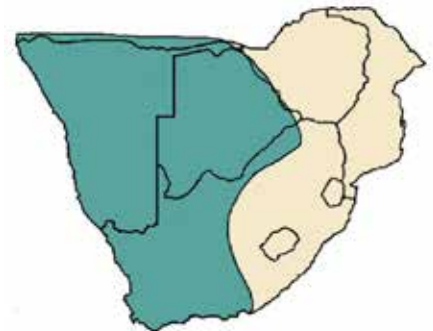


Fig. 3 Distribution maps of *P. granulatus* (top) and *P. transvaalicus* (bottom).¹

fallen trees, and in soils of variable hardness and texture ranging from consolidated sand to moderately hard and gritty sediments. Some, for example *P. granulatus*, are often found near human habitats (e.g. suburban gardens and farm yards).¹ *P. granulatus* also have a habit of actively foraging unlike most other scorpions' sedentary ambush strategy, adding to the reason for the high number of envenomations by *P. granulatus*.^{2,6}

Mechanism of action of venom

Although differences exist in the composition of the venom of different scorpion species⁷, the clinical profile of scorpionism (scorpion sting associated with symptoms and signs of systemic envenoming) primarily reflects a state of generalised neurological hyperexcitability. Other excitable tissue, such as skeletal and heart muscle, may also be affected.^{1,6,8} Fig. 4 shows the mechanism of action of the neurotoxic venom on the peripheral nervous system.¹

These mechanisms may explain the sympathetic,

Mechanisms of action of neurotoxic venoms on the peripheral nervous system

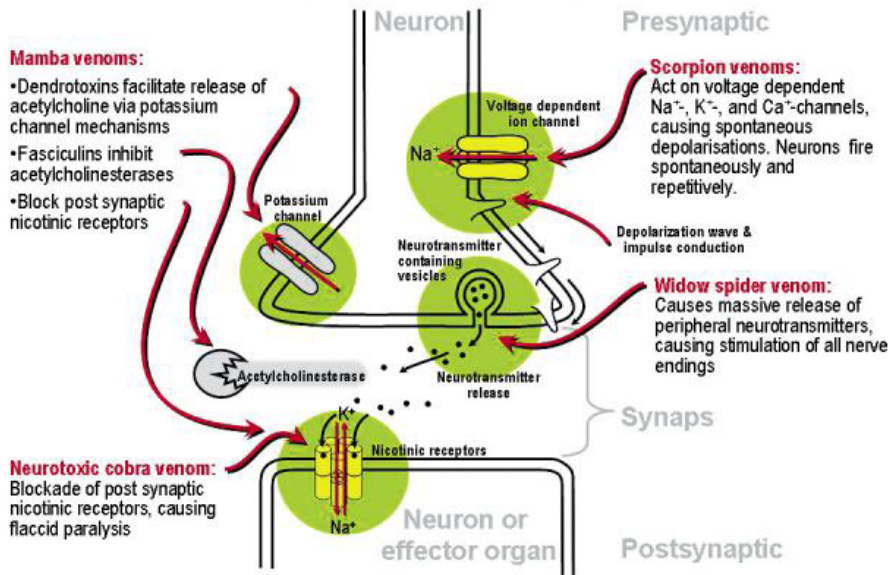


Fig. 4 Mechanisms of action of neurotoxic venoms on the peripheral nervous system.¹

para-sympathetic and skeletal muscle effects of scorpion venom. Symptoms and signs of increased sympathetic activity include hypertension, tachycardia, cardiac dysrhythmias, increased perspiration, fever, hyperglycaemia and restlessness. An increase in catecholamine levels has been demonstrated in severe envenomings. Hypertension may also be induced by an increase in renin release. Parasympathetic effects include increased salivation, bradycardia, hypotension and gastric distension. Tremors and involuntary movements seen in scorpionism are due to excessive somatic neuromuscular activity. Muscle weakness, difficulty in breathing and bulbar paralysis could be explained by a phase of relative neurotransmitter depletion after excessive neuronal activity.^{1,8}

Diagnosis and clinical signs

The spectrum and degree of symptoms and signs of systemic envenoming are determined by several factors:

- the scorpion species involved and the degree of agitation of the scorpion
- the site and depth of the sting
- the amount of venom injected
- the physical health and body mass of the patient^{1,2,8}

Immediate pain is the most prominent symptom in humans, often described as burning and of an excruciating intensity. The pain lasts for a variable period, usually extending from hours to a day and sometimes even longer. It is usually accompanied by paraesthesia (“pins and needles”) in the hands, feet, face and scalp as well as pronounced hyperaesthesia. Muscle pain and cramps are prominent. Human patients sometimes describe a

sensation of vibration and experience a feeling akin to an electrical current moving through the body.^{1,2,8}

Muscle weakness, tremors and ataxia are also common symptoms in humans. Some patients experience visual disturbances and a substantial number have difficulty breathing.^{1,2,6,8}

Other symptoms described in humans include anxiety, involuntary movements, bulbar paralysis characterised by dysphagia (esp. with *P. transvaalicus*), dysarthria and drooling with varying degrees of loss of pharyngeal reflexes. Increased salivation is typical. The blood pressure and temperature are often raised and the tendon reflexes are hyper-reactive. Clonus may be present. Ptosis and urine retention may be present in a substantial number of humans.^{1,2,6,8} Nausea, vomiting, diarrhoea and headaches may also be present.²

Although children may present with symptoms and signs similar to those seen in adults, the most outstanding clinical feature is a unique form of restlessness. It is characterised by crying and screaming, uncontrollable jerking of the extremities, chaotic thrashing movements, flailing and writhing. The patient is unable to lie still and is difficult to restrain. He or she may assume an unnatural posture and contract the face in a simulated chewing motion, with grimaces and smacking of the lips. The restlessness caused by scorpionism in children has been described as ‘extraordinary and duplicated by little else in medicine’. The smaller child or infant may, however, present with unexplained crying only.¹

Respiratory failure is the most dangerous feature of severe scorpionism and is usually the primary

cause of death. Severe cardiovascular manifestations such as cardiac dysrhythmias, pulmonary oedema and cardiac failure, which are often associated with scorpionism in other regions of the world are not such a prominent feature in southern Africa.^{1,8} In humans tachycardia (pulse rate of 100-150bpm) for *P. granulatus* and below 55bpm for *P. transvaalicus* is seen.² Although a high percentage of patients present with raised blood pressure (esp in *P. granulatus* cases), this is not a consistent finding.^{1,6} The difference in heart rate seen in cases of *P. granulatus* vs *P. transvaalicus* envenoming could possibly be explained by the different peptides in the venom.⁷

In animals a diagnosis depends on good history taking and observation of symptoms, since the owner often does not see the scorpion when it stings the animal.

Animals are typically stung on the front feet or face after sundown, usually outside the house. Veterinarians who have treated animals stung by scorpions reported the following clinical observations:

- 1) Severe pain (esp. in the region of the spleen) starting anything from 30 minutes to 3 hours after being stung
- 2) Tense abdominal muscles
- 3) Uncharacteristic aggression
- 4) Severe salivation
- 5) Mydriasis
- 6) Tachycardia
- 7) Pyrexia
- 8) Bloodsmear with stress leukogram within an hour
- 9) Mild hyperglycaemia
- 10) Mild hypertension
- 11) Chewing motions or smacking of the jaws/lips
- 12) Dry cough (or throat irritation) develops after about 24 hours – esp. in patients that did not receive antivenom

Differential diagnosis

The diagnosis of scorpionism can sometimes be difficult in the absence of a firm history of a sting. Differential diagnosis may include the following:

Spider bites, snake bites, organophosphates/carbamates, tetanus, botulism, myasthenia gravis, encephalitis/meningitis, polyradiculoneuritis and cranial trauma.^{1,2,3}

Table 1 compares the major symptoms and signs of scorpionism, latrodectism (spider bite) and neurotoxic cobra bite as seen in humans.¹

Treatment

One of the reasons for writing this article is because there seems to be confusion and disagreement between clinicians about the treatment of animals that was stung by a scorpion. What we propose here is a combination of what we found when discussing it with different veterinarians and also what we found in the literature on treatment in humans.

- Antivenom (SAIMR Scorpion antivenom; containing serum globulins obtained from horses immunized with *P. transvaalicus* venom and supplied in 5ml vials) can be given IV to all patients showing signs of systemic envenoming. It works well, but it is very expensive (around R1500 per vial at the moment) and therefore not all clients can afford it. In humans it takes 2-6 hours to reach its peak effect. Dogs seem to be fully recovered within 6 hours of giving the antivenom. Allergic/anaphylactic reactions to the antivenom may develop. The prophylactic administration of adrenaline intramuscularly to prevent serious allergic reactions is controversial because it may increase the effects of sympathetic nervous system stimulation by the scorpion venom.
- The routine use of antihistamines and glucocorticosteroids is not recommended unless they are administered to decrease the severity of a possible allergic reaction to the antivenom.
- Do not administer barbiturates, opiates, morphine or morphine derivatives as this could greatly increase convulsions and cause respiratory distress, vomiting and aspiration.²
- In human medicine they found treatment with non-steroidal anti-inflammatory agents disappointing. However, in dogs we found they respond very well to non-steroidal anti-inflammatories. Drugs mentioned by different veterinarians include meloxicam (Metcam, Petcam), flunixin meglumine (Finadyne) and robenacoxib (Onsior). Ketamine can also be used.
- Sedation is important. Some clinicians use acetylpromazine, while others use diazepam because of its muscle relaxation and anxiolytic properties.
- The use of atropine is also controversial. It appears that atropine can be used in cases of confirmed *P. transvaalicus* envenomation to control excessive secretions; however, the use of atropine to reduce secretions is not advisable in cases of *P. granulatus* stings as this may lead to unopposed adrenergic responses.²
- Placing a drip is controversial because of the possible hypertension. Intravenous fluid therapy should therefore be closely supervised to prevent vascular overload.

Table 1. Comparison of major symptoms and signs of scorpionism, latrodectism and neurotoxic cobra bite

Symptoms and signs of envenomation	Scorpionism	Latrodectism	Neurotoxic cobra bite
Local symptoms and signs			
Degree of local physical signs (bite or sting site)	(+)	+	++
Local pain	++++	+	++
Regional lymph nodes, pain and swelling	+	+++	+
Systemic symptoms and signs			
Generalised muscular pain	++(+)	++++	-
Muscle tone: extremities, abdomen and chest	+(+)	+++	-
Paraesthesia, hyperaesthesia	++++	+	-
Dysphagia, dysarthria,	++++	-	+++
Involuntary movements, tremor, fasciculations	++++	++	+
Hyperactivity, restlessness	++++*	++	-
Stretch reflexes	+++	++	-
Flaccid paralysis	-	-	++++
Difficulty in breathing, requiring vent. support	+++*	-	++++
Ophthalmoplegia	(+)	-	++++
Ptosis	++	-	++++
Autonomic dysfunction:			
• pulse rate: fast or slow, ↑ blood pressure	+++**	+++	(+)
• sweating ↑	++	+++(+)	+
• temperature ↑	++	+	(+)
• salivation ↑ upper respiratory secretions*	++++	-	++

* Children especially.

** Species differences, e.g. *P. granulatus*: ↑ pulse rate; *P. transvaalicus*: ↓ pulse rate.

- It is not often that you can find the sting site, but if you do, you can treat with a local anaesthetic agent (lignocaine) or ice.
- Slow intravenous administration of calcium gluconate 10% (10 ml over 10 min) is moderately effective for the relief of generalised muscle pain and cramps in humans, but its effect lasts for 20 - 30 minutes only and there is a limit to the amount that can be administered safely.¹ Slow IV infusion of magnesium-sulphate-doped Ringer's lactate (1 vial in a litre of Ringers given over 12 hours) might also help for the pain.⁴
- Some veterinarians give an antibiotic to prevent infection at the sting site.
- If the patient develops severe tachycardia (it seems like a large dose of *P. transvaalicus* venom can cause myocarditis) put the patient on prazosin or xatral, which are Alpha-2-agonists available from a local pharmacy.⁵
- Special investigations which may assist in assessment and treatment include: pH and electrolytes, acid-base balance, arterial blood gases and an ECG where applicable.¹

Conclusion

- Most local scorpions are relatively harmless, and although they can inflict quite a painful sting, other toxic effects are not expected to develop. However, a small number of scorpion species can cause life-threatening systemic

envenoming in humans and animals.

- Most deaths are attributable to one species, namely *P. granulatus*.
- The traditional rule of thumb that scorpions with thick tails and slender pincers are more venomous than those with slender tails and large pincers is a useful guide for the clinician.
- The diagnosis of scorpionism usually depends on a good history as well as clinical signs.
- The patient shows generalised neurological hyperexcitability and severe pain. Severe salivation and aggression is also seen.
- Differential diagnosis include neurotoxic spider and snake bite.
- Scorpion antivenom can be given to all patients with symptoms and signs of systemic envenoming, but cost constraints might apply.
- Allergic/anaphylactic reactions to the antivenom may occur.
- Analgesia includes NSAID and ketamine. Do not administer barbiturates, opiates, morphine or morphine derivatives as this could greatly increase convulsions and cause respiratory distress, vomiting and aspiration.
- Sedation is important. Some clinicians use ACP, while others use diazepam because of its muscle relaxation and anxiolytic properties.

Multiple-choice questions

(Choose one answer)

QUESTION 1:

The most dangerous and medically important species of scorpions all belong to the following family:

- Scorpionidae*
- Buthidae*
- Bothriuridae*
- Liochelidae*
- Luridae*

QUESTION 2:

Which combination of statements regarding scorpions are correct?

- Scorpions with thick tails and slender pincers are more venomous than those with slender tails and large pincers.
 - Scorpions with slender tails and large pincers are more venomous than those with thick tails and slender pincers.
 - Scorpions are mostly active during summer months.
 - Scorpions are mostly active during winter months.
 - Most scorpion species are nocturnal.
 - Most scorpion species are diurnal.
- 1, 3, 5
 - 2, 4, 6
 - 1, 4, 5
 - 2, 3, 6
 - 2, 3, 5

QUESTION 3:

Which statement about *P. Granulatus* is correct?

- P. granulatus* is two times more venomous than *P. transvaalicus*.
- P. granulatus* is dark brown to uniformly black.
- P. granulatus* have an ambush strategy to catch its prey.
- P. granulatus* is often found near human habitats.
- P. granulatus* measures 50-80mm in length.

QUESTION 4:

The mechanism of action of scorpion venom is:

- Dendrotoxins facilitate release of acetylcholine via potassium channel mechanisms.
- Acts on voltage dependent Na⁺, K⁺ and Ca⁺-channels causing spontaneous depolarisations.
- Blockade of post-synaptic nicotinic receptors, causing flaccid paralysis.
- Massive release of peripheral neurotransmitters, causing stimulation of all nerve endings.
- Blockade of the neurotransmitter release from spinal inhibitory interneurons.

REFERENCES

- Müller *et al.* Scorpion sting in southern Africa: diagnosis and management. <http://www.cmej.org.za/index.php/cmej/article/view/2545/2580#>.
- Scorpion stings and venoms. http://www.biodiversityexplorer.org/arachnids/scorpions/stings_and_venoms.htm
- Tilley, LP & Smith, FWK. The 5-minute Veterinary Consult.
- Aksel *et al.* A randomized trial comparing intravenous paracetamol, topical lidocaine, and ice application for treatment of pain associated with scorpion stings. *Human and Experimental Toxicology*. 2014 Oct 10. Pii: 0960327114551394.
- Zambelli, AB. Personal communication, 2014.
- Elston, DM. What's eating you? The South African Fattail Scorpion (*Parabuthus transvaalicus*). Close encounters with the environment. *Cutis*, Volume 76, November 2005.
- Dyason *et al.* Determination of species-specific components in the venom of *Parabuthus* scorpions from southern Africa using matrix-assisted laser desorption time-of-flight mass spectrometry. *Rapid Communications in Mass Spectrometry*, 16: 768-773, 2002.
- Müller, GJ. Scorpionism in South Africa – A report of 42 serious scorpion envenomations. *South African Medical Journal*, Volume 83, p405-411, June 1993.

QUESTION 5:

The most dangerous feature of severe scorpionism in humans (and possibly dogs) is:

- tachycardia leading to fibrillation.
- bulbar paralysis leading to dysphagia.
- respiratory failure.
- pulmonary oedema.
- clonus.

QUESTION 6:

Which of the following symptoms is NOT associated with scorpionism in dogs:

- Severe salivation
- Bradycardia
- Severe pain
- Tense abdominal muscles
- Chewing motions/lip smacking

QUESTION 7:

Which of the following is NOT a DD for scorpionism in dogs:

- Organophosphate poisoning
- Tetanus
- Polyradiculoneuritis
- Otitis media
- Botulism

Question 8:

Which statement about scorpion antivenom is true?

- It contains serum globulins obtained from cattle immunized with *P. transvaalicus* venom.
- It is very cost effective.
- In humans it takes 30 minutes to reach it peak effect.
- The prophylactic administration of adrenaline intramuscularly to prevent allergic reactions is advised.
- It can be given IV to all patients showing signs of systemic envenoming.

QUESTION 9:

The following is contraindicated when treating a dog stung by a scorpion:

- Buprenorphine
- Ketamine
- Flunixin
- Acetylpromazine
- Meloxicam

QUESTION 10:

A good treatment protocol for a dog stung by *P. granulatus* would be:

- Antivenom, meloxicam, acetylpromazine, atropine.
- Antivenom, morphine, diazepam, lignocaine.
- Robenacoxib, antihistamine, diazepam, calcium gluconate.
- Antivenom, meloxicam, diazepam, acetylpromazine.
- Meloxicam, butorphenol, diazepam, lignocaine.